

Successful Surgical Treatment of a Right Atrial Myxoma Associated with Pulmonary Embolism

Eurasian Clinical and Analytical Medicine Case Report

Surgical Treatment of a Right Atrial Myxoma

Kemal Korkmaz, Ali Baran Budak, Serhat Bahadır Genç, Hikmet Selçuk Gedik, Kerim Çağlı
Cardiovascular Surgery Clinic, Ankara Numune Training and Research Hospital, Ankara, Turkey

Abstract

In all of the tumors seen in humans, cardiac tumors have very small presentation as 0.2%. These tumors have mainly metastatic origin and only a small percent of them are primary tumors. We present a 30-year-old male patient with a right atrial mass who had acute pulmonary embolism. He underwent right atrial mass resection with concomitant pulmonary thrombectomy. Pathologic examination revealed right atrial myxoma. In this case report, we discussed this rare tumor with preoperative and postoperative imaging via transthoracic and transesophageal echocardiography.

Keywords

Right Atrial Myxoma; Pulmonary Embolism; Interatrial Septum

DOI:10.4328/ECAM.37

Received : 14.09.2014

Accepted : 14.09.2014

Published Online : 16.09.2014

Printed Online : 16.09.2014

Eu Clin Anal Med 2014;2[2]: 12-4

Corresponding Author: Kemal Korkmaz, Ankara Numune Eğitim ve Araştırma Hastanesi, Kalp ve Damar Cerrahisi Kliniği, 06100, Ankara, Türkiye.
GSM: +90 505 572 61 11 • **P:** +90 312 508 4285 • **P:** +90 312 311 43 40 • **E-Mail:** kemalkorkmaz44@hotmail.com

How to cite this article: Kemal Korkmaz, Ali Baran Budak, Serhat Bahadır Genç, Hikmet Selçuk Gedik, Kerim Çağlı. Successful surgical treatment of a right atrial myxoma associated with pulmonary embolism. Eu Clin Anal Med 2014;2[2]: 12-4.

Introduction

Cardiac tumors can be primary, secondary or metastatic and represent 0.2% off all tumors seen in humans [1]. Primary intracardiac tumors are rarely found and approximately 75% are benign and among them 50% are myxomas. Myxomas derive from multipotent mesenchymal cells of the subendocardium [1,2]. They are mostly seen in left atrium, but may arise in other locations such as right atrium (RA) in 15% to 20% of cases [3]. According to the mobility, size and location of the tumor, symptoms are atypical and highly variable resulting in diagnostic confusion and significant delay in diagnosis. When located in the RA, myxoma can manifest pulmonary embolism rarely, as in our case.

Case Report

A 30-year-old man, presented with sudden episode of dyspnea, palpitation and atypical chest pain. He also had suffered from weight loss and intermittent feeling faint for the past one year.

Physical examination was unremarkable. Chest X-ray showed moderate enlargement of the cardiac silhouette with normal pulmonary fields. Standard electrocardiogram showed sinus tachycardia with a heart rate of 120bts/min and incomplete right bundle branch block. D-dimer value was in normal range (192 ng/ml).

Contrast enhanced computed tomography (CT) revealed partial obstruction of right pulmonary artery and the main pulmonary artery was free of lesion. Venous doppler study of the low extremity showed normally functioning deep veins with no sign of acute or chronic deep vein thrombosis.

After the completion of these tests, clinic of chest diseases hospitalized the patient to their clinic and initiated anticoagulant and antiaggregant therapy for PE. The d-dimer values stayed constant and the complaints of the patient did not decrease. They consulted the patient to us and a transthoracic echocardiogram (TTE) was planned.

TTE revealed a 30x24 mm moving mass attached to the interatrial septum of the right atrium and slightly reduced right ventricular function but it cannot differentiate the diagnosis as if the mass was a tumor or thrombus.

Thus a transesophageal echocardiography was conducted and it revealed a 40x27 mm mobile mass with multilobular heterogeneous echogenicity attached to the interatrial septum of the right atrium, which was prolapsing through the leaflets of the tricuspid valve during diastole and not affecting the blood flow in the superior or inferior vena cava. In the light of these findings, we admitted the patient to our clinic. After taking written informed consent, open-heart surgery was arranged. A standard midline sternotomy incision was performed. Following full systemic heparinization, ascending aortic and bicaval selective cannulation using two standard 28-Fr venous return cannulas in order to avoid tumor embolization established cardiopulmonary bypass. Myocardial protection was provided by antegrade cold crystalloid cardioplegia and moderate systemic hypothermia (28°C). The right atrium was opened and a large pedunculated tumor originated from the atrial septum was removed with a cuff of normal adjacent septum tissue.

The resected mass was sent for histological assesment. The iatrogenic atrial septal defect was repaired using a pericardial patch.

After that, main pulmonary artery was opened under intermittent total circulatory arrest (7 min in total) and a 1-cm-diameter tumor fragmentation was removed from the right pulmonary artery. Arteriotomy of the pulmonary artery was closed and the procedure was concluded. Perioperative TEE confirmed normal function of the tricuspid valve and the absence of residual masses.

The patient was transferred to the intensive care unit with 5- μ g/kg/min dobutamine infusion. The postoperative course was uncomplicated. The patient was discharged on the postoperative 7th day.

The histopathologic examination confirmed the tumor etiology as a myxoma.

10 days after discharge, the patient was admitted to our clinic suffering from atrial fibrillation with rapid ventricular response. The normal sinus rhythm was established by intravenous amiodarone. Follow-up TTE revealed normally functioning tricuspid valve, a pulmonary artery pressure of 27 mmHg with no sign of residual mass.

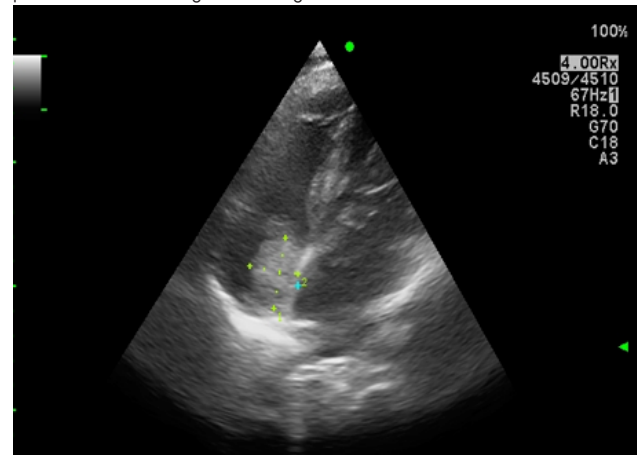


Figure 1. Preoperative TTE image of Right Atrial Myxoma

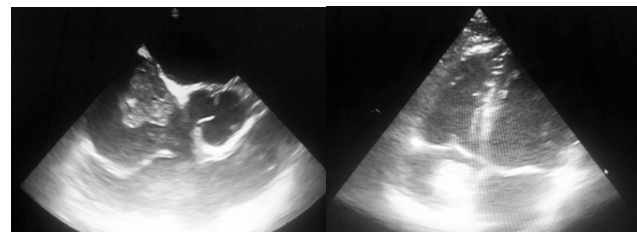


Figure 2. Preoperative TEE image of Right Atrial Myxoma

Video1 and Video 2. Preoperative Moving TEE Image of Right Atrial Myxoma

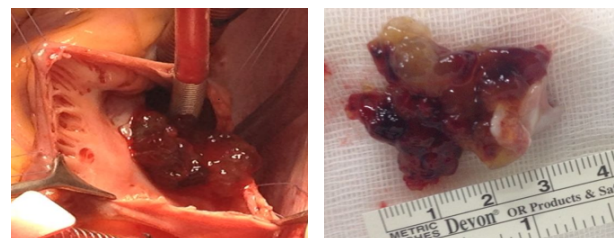


Figure 3. Perioperative Image of Right Atrial Myxoma

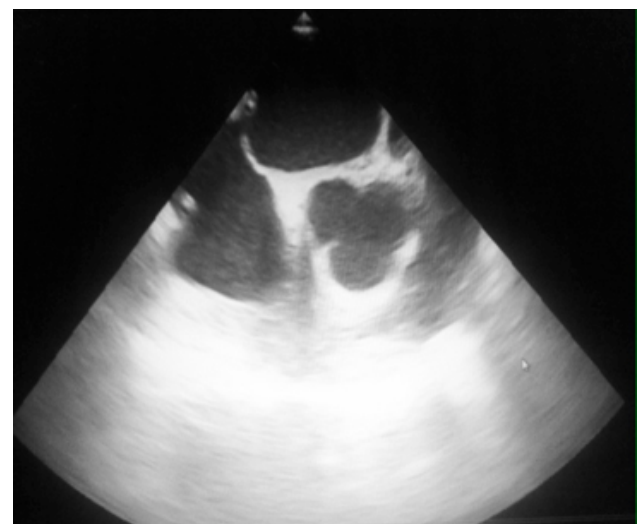

Figure 4. Perioperative TEE Image After From Right Atrial Myxoma Resection

Video 3. Perioperative Moving TEE Image After From Right Atrial Myxoma Resection

Discussion

Myxoma is the most prevalent primary cardiac tumor. The incidence of RA localization is low. Yu and colleagues retrospectively reviewed 33108 patients who underwent open-heart surgery and reported 234 cases with a confirmed diagnosis of primary heart tumor (0.71%). Among 184 patients with myxoma, RA localization was found only in 12 (6.5%) cases [4]. RA myxomas generally originate in the fossa ovalis or base of the interatrial septum [5]. In regard to the macroscopic aspect, 83% of myxomas are polypoid and pedunculated tumors with a predominant brownish color, as in our case [3].

Myxomas usually present themselves insidiously resulting in a delay in their diagnostic and surgical management. They may appear with obstruction symptoms due to blood flow blockade or with symptoms due to embolism, arrhythmia and constitutional symptoms due to tumor embolization and /or complement activation from circulating antibody tumor antigen complexes [6].

Embolization from a thrombotic material from deep veins, right heart chambers or catheter tips are the most common reasons of pulmonary embolism. D-dimer levels are usually elevated in plasma in the presence of acute thrombosis, because of simultaneous activation of coagulation and fibrinolysis. The negative predictive value of D-dimer testing is high and a normal D-dimer level renders acute PE or deep vein thrombosis. Furthermore, cancer or inflammation can produce fibrin also. According to the 2014 ESC Guideline on the diagnosis and management of acute PE, if there is suspected PE without shock or hypotension and if the D-dimer is negative, no treatment is suggested [7]. Embolism occurs in approximately 10% cases of RA myxoma, and even pulmonary embolism of tumor fragments or thrombus from the tumor surface can occur, as in our case.

However, as depicted in our case, although the patient has non-specific symptoms and D-dimer is normal, TTE evaluation should be planned in every patient with pulmonary embolism. In our case, TTE revealed a 30x24 mm moving mass attached to the interatrial septum of the right atrium and slightly reduced right ventricular function. In our experience, TEE should be considered in patients with RA masses which were demonstrated with TTE because its sensitivity is better than TTE, computed tomography or magnetic resonance imaging [8]. Also we strongly recommend to use TEE during surgery because it provides useful information to secondary valve damage caused by the tumor or to diagnose rare biatrial or multilocular myxomas.

Complete removal of the tumor and its implantation base with a good safety margin is important for maintaining contractility, preventing pulmonary embolism and recurrence and restoring dilatation functions of bilateral atria. In this case, the tumor was located in fossa ovalis of RA and removed with a cuff of normal adjacent septum tissue.

Pulmonary embolectomy is a surgical procedure that evolved in the last 20 years. The procedure should be considered in cases of myxoma associated with PE in order to prevent right ventricle dysfunction and to improve patient symptoms.

Conclusion

RA is an unusual location for myxoma and it has a potential of pulmonary embolism. Although the patient has non-specific symptoms and D-dimer is normal, TTE evaluation should be planned in every patient with pulmonary embolism. TEE is a sufficient and reliable technique for diagnosis and evaluation of shape, size and the origin of the myxoma. It is also an adequate guide to surgical treatment. RA myxoma associated with pulmonary embolism should urgently be treated with surgical removal and pulmonary embolectomy.

Scientific Responsibility Statement

The authors declare that they are responsible for the article's scientific content including study design, data collection, analysis and interpretation, writing, some of the main line, or all of the preparation and scientific review of the contents and approval of the final version of the article.

Animal and human rights statement

All procedures performed in this study were in accordance with the ethical standards of the institutional and/or national research committee and with the 1964 Helsinki declaration and its later amendments or comparable ethical standards. No animal or human studies were carried out by the authors for this article.

Funding: None

Conflict of interest

None of the authors received any type of financial support that could be considered potential conflict of interest regarding the manuscript or its submission.

References

1. Arruda MV, Braile DM, Joaquim MR, Soares MJ, Alves RH. Resection of left ventricular myxoma after embolic stroke. *Rev Bras Cir Cardiovasc*. 2008 Oct-Dec;23(4):578-80
2. Jang KH, Shin DH, Lee C, Jang JK, Cheong S, Yoo SY. Left atrial mass with stalk: thrombus or myxoma? *J Cardiovasc Ultrasound*. 2010 Dec;18(4):154-6.
3. Vinicius JS, Nina, Nathalia AC, Silva, Shirlyne FD, Gaspar, Thaisa L, Rapôso, Eduardo C, Ferreira, Rachel VAH, Nina, Joyce S, Lages, Fernando ACC, Silva and Natalino Salgado Filho. Atypical size and location of a right atrial myxoma: a case report. *Journal of medical case reports* 2012, 6:26
4. Yu K, Liu Y, Wang H, Hu S, Long C. Epidemiological and pathological characteristics of cardiac tumors: a clinical study of 242 cases. *Interact Cardiovasc Thorac Surg*. 2007;6:636-639
5. Stolf NA, Benicio A, Moreira LF, Rossi E. Right atrium myxoma originating from the inferior vena cava: an unusual location with therapeutic and diagnostic implications. *Rev Bras Cir Cardiovasc*. 2000;15:255-258.
6. Leonardo Secchin Canale, Alexandre Siciliano Colafranceschi, Eduardo Souza Leal Botelho and Andrey José de Oliveira Monteiro. Surgical treatment of right atrial myxoma complicated with pulmonary embolism. *Interact Cardiovasc Thorac Surg*. 2009 Sep;9(3):535-6. doi: 10.1510/icvts.2009.206318. Epub 2009 Jun 2.
7. ESC Guidelines on the diagnosis and management of acute pulmonary embolism: The Task Force for the Diagnosis and Management of Acute Pulmonary Embolism of the European Society of Cardiology (ESC) [Endorsed by the European Respiratory Society (ERS)]. *Eur Heart J*. 2014 Aug 29. pii: ehu283.
8. Leibowitz G, Keller NM, Daniel WG, Freedberg RS, Tunick PA, Stottmeister C, Kronzon I. Transesophageal versus transthoracic echocardiography in the evaluation of right atrial tumors. *Am Heart J*. 1995 Dec;130(6):1224-7.